Congenital Heart Disease

Dr B. Ombaba Osano
Paediatrics & Child Health
CHS - UoN

Just an introduction

- Best to get full details for each condition from the textbooks

CHD and embryology

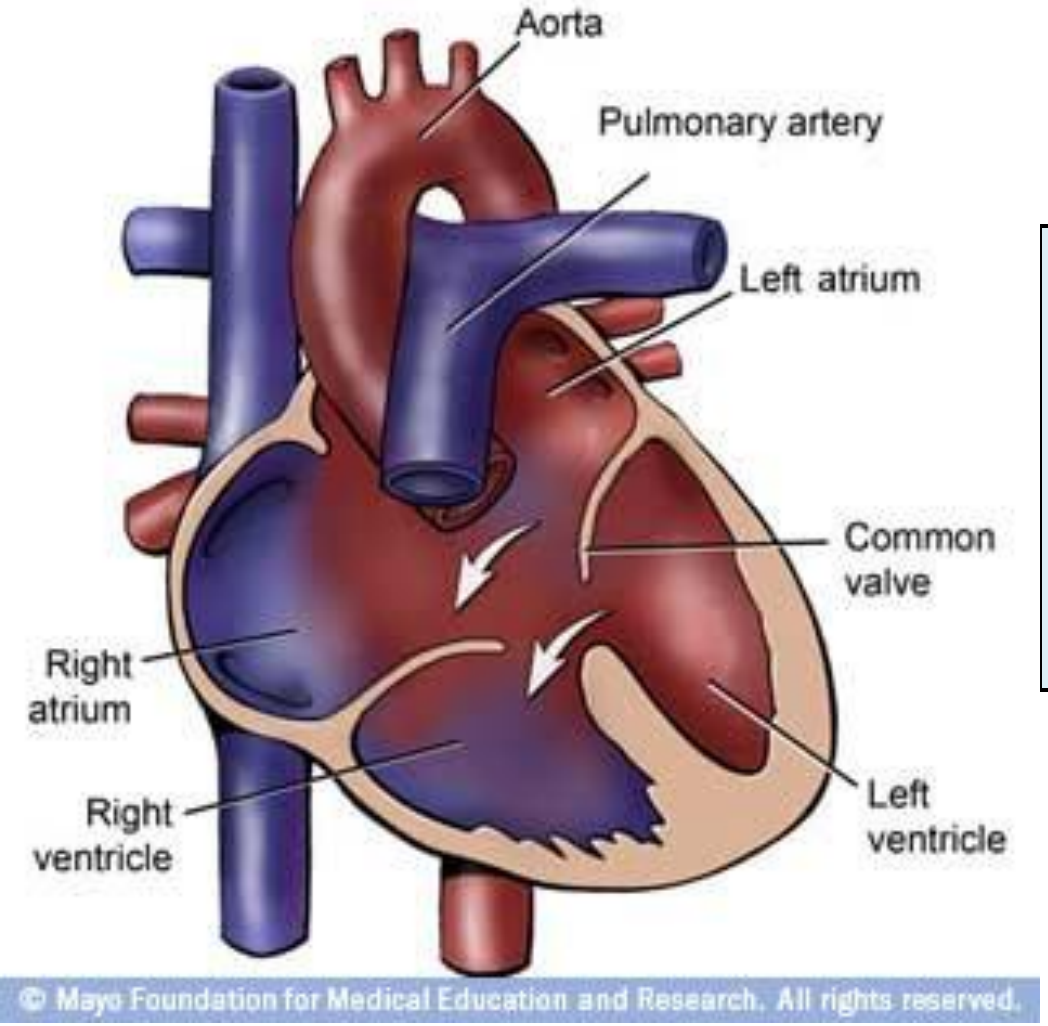

- **Understand Heart embryology as the basis for Congenital Heart disease**

Heart Lung relations

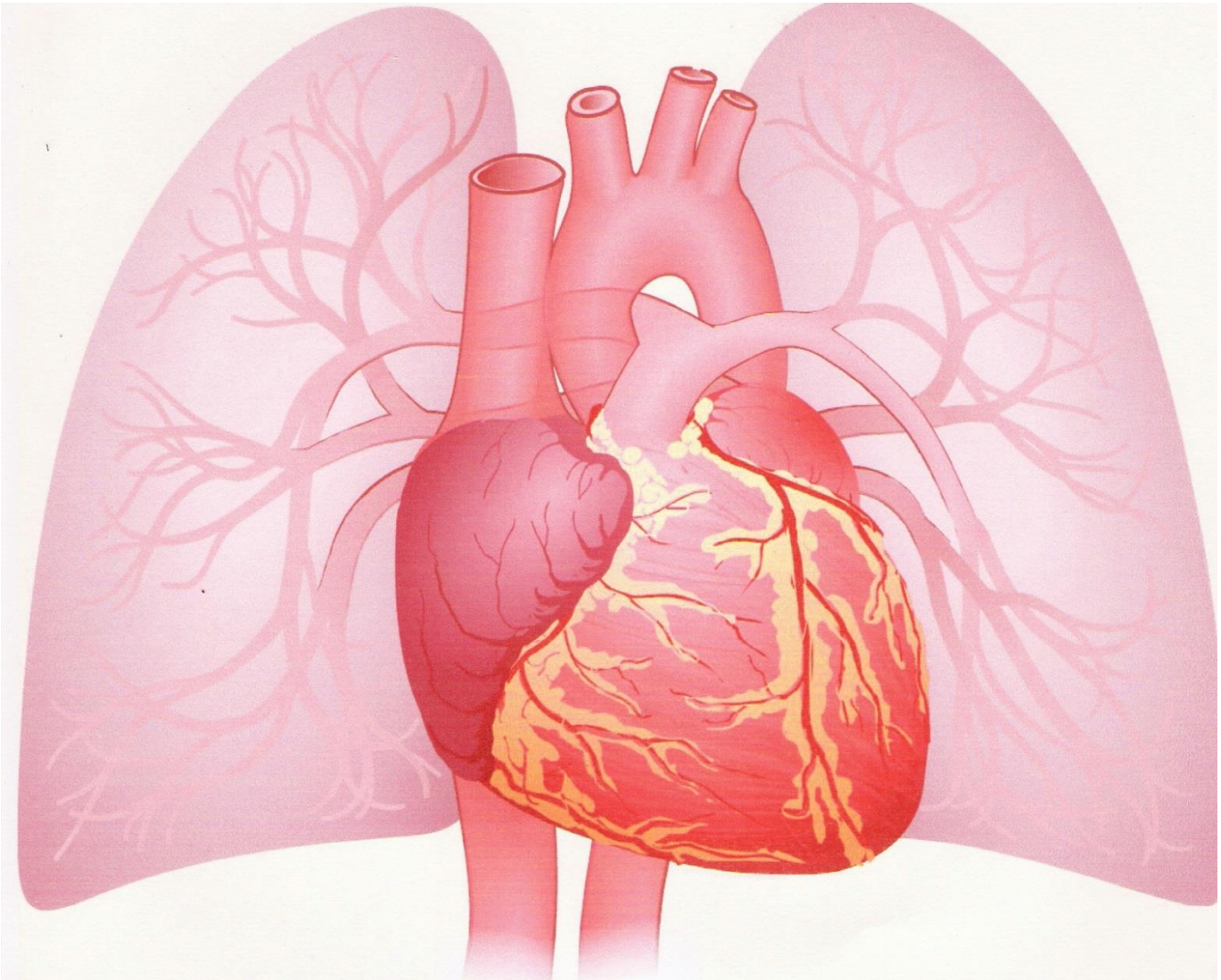

Heart Embryology at a Glance

Weeks	Days	Cardiac Events
1-2	0-20	No heart or great vessels
3	20	Cardiogenic plate
3	21	Endocardial tubes
4	22	Fusion of endocardial tubes
4	23	Single median cardiac tube,first contraction (ineffective)
4	25	Cardiogenic loop
4	26	Single atrium
5	29	Bi-lobed atrium
5	30	Beginning of circulation
5	31	Septum primum
5	35	A-V orifice, 3 chamber heart
6	36	Septum secundum
6	39	Complete inferior septum
6	40	Septation of bulbus and ventricle
6	42	Divided truncus arteriosus
7	49	4-chambered heart, Absorption of pulmonary veins

Early Heart Tube Differentiation

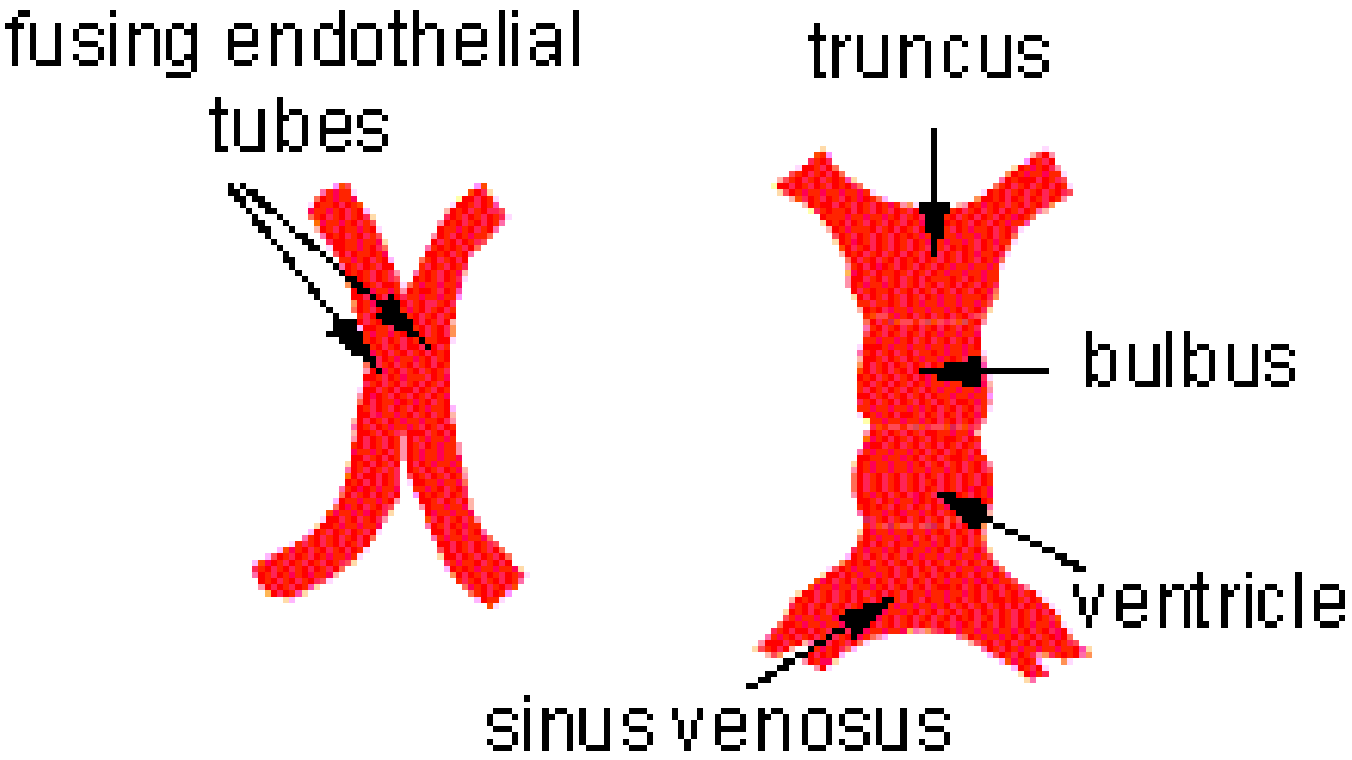

Early Heart Tube Differentiation

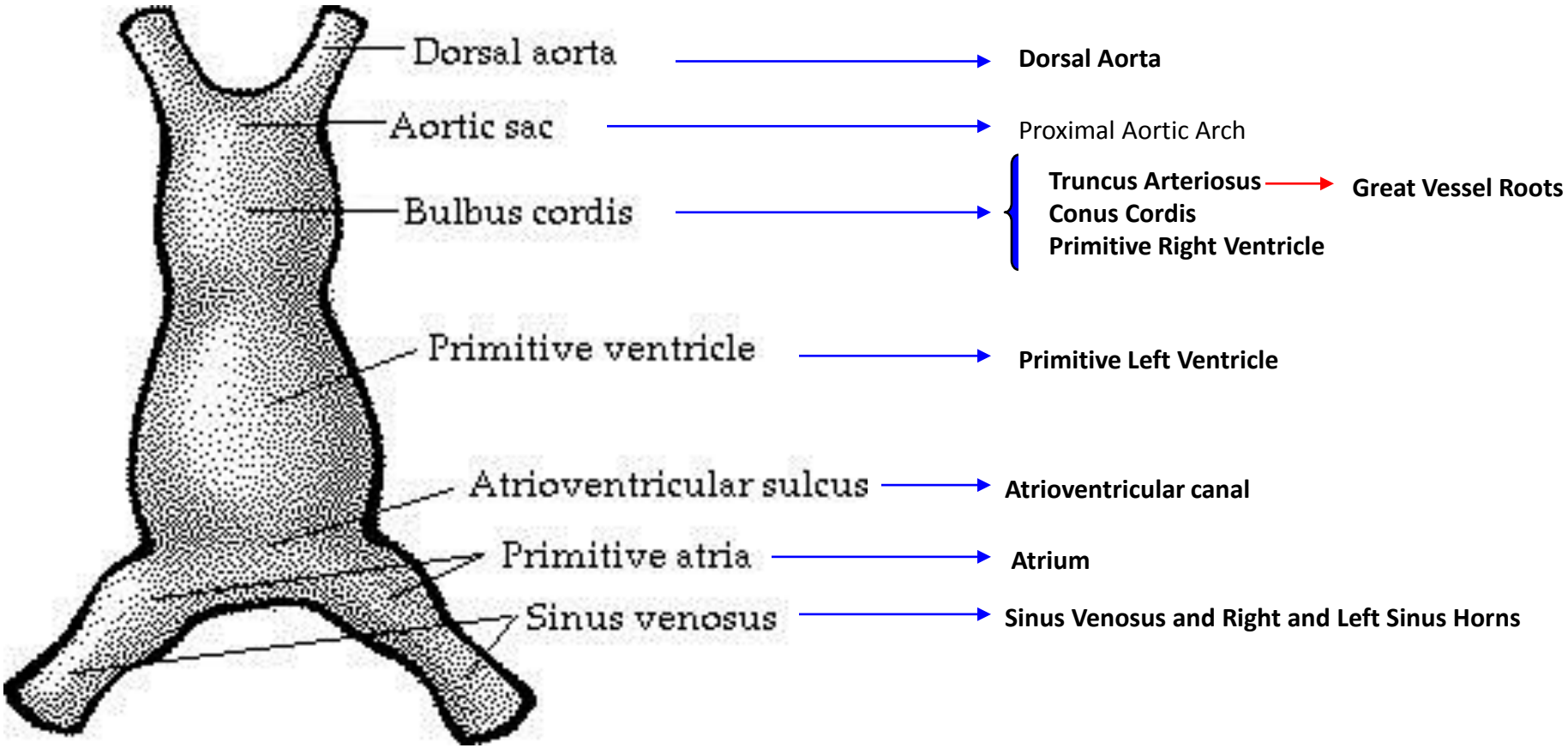

Cardiac Looping

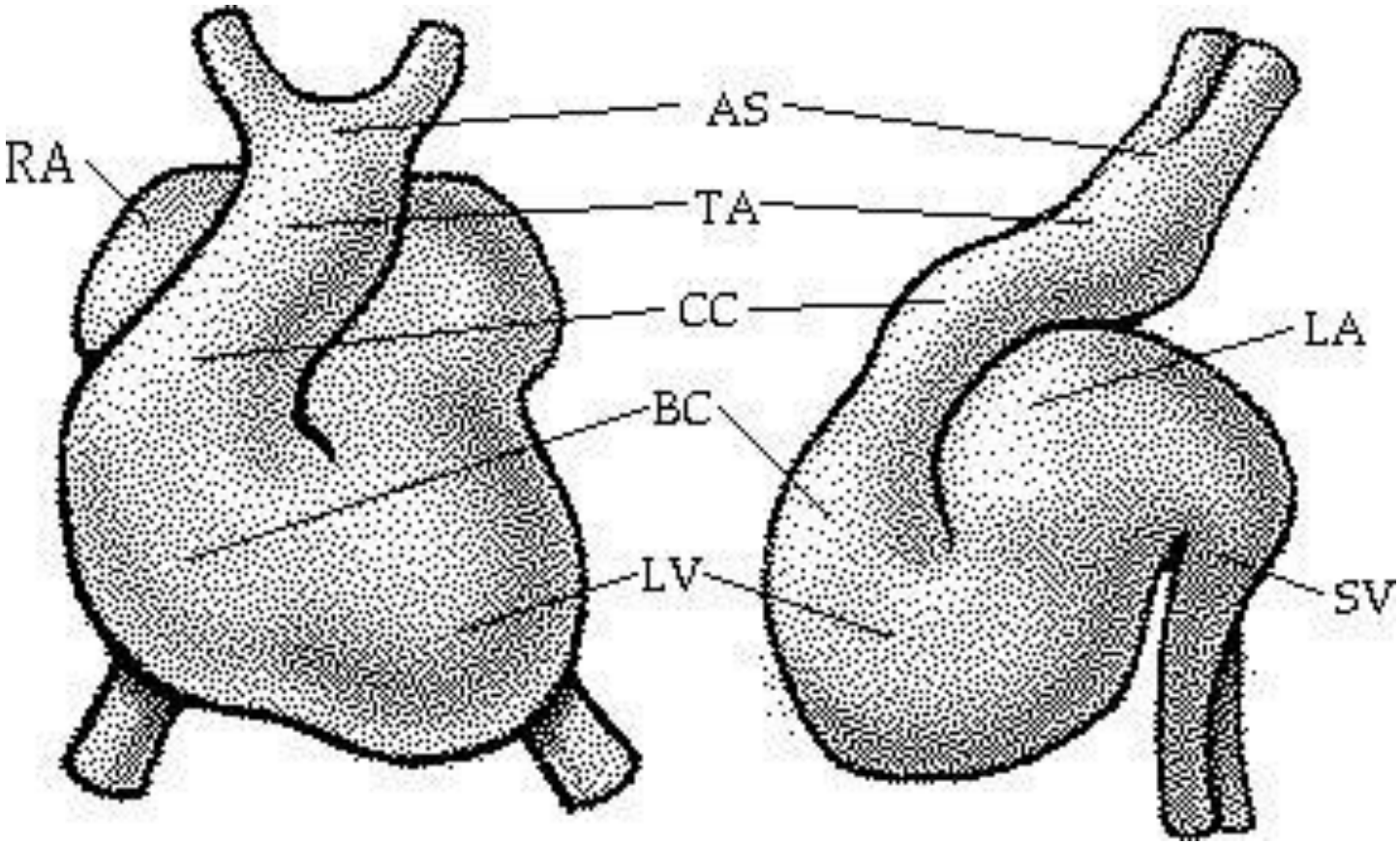

Anatomy

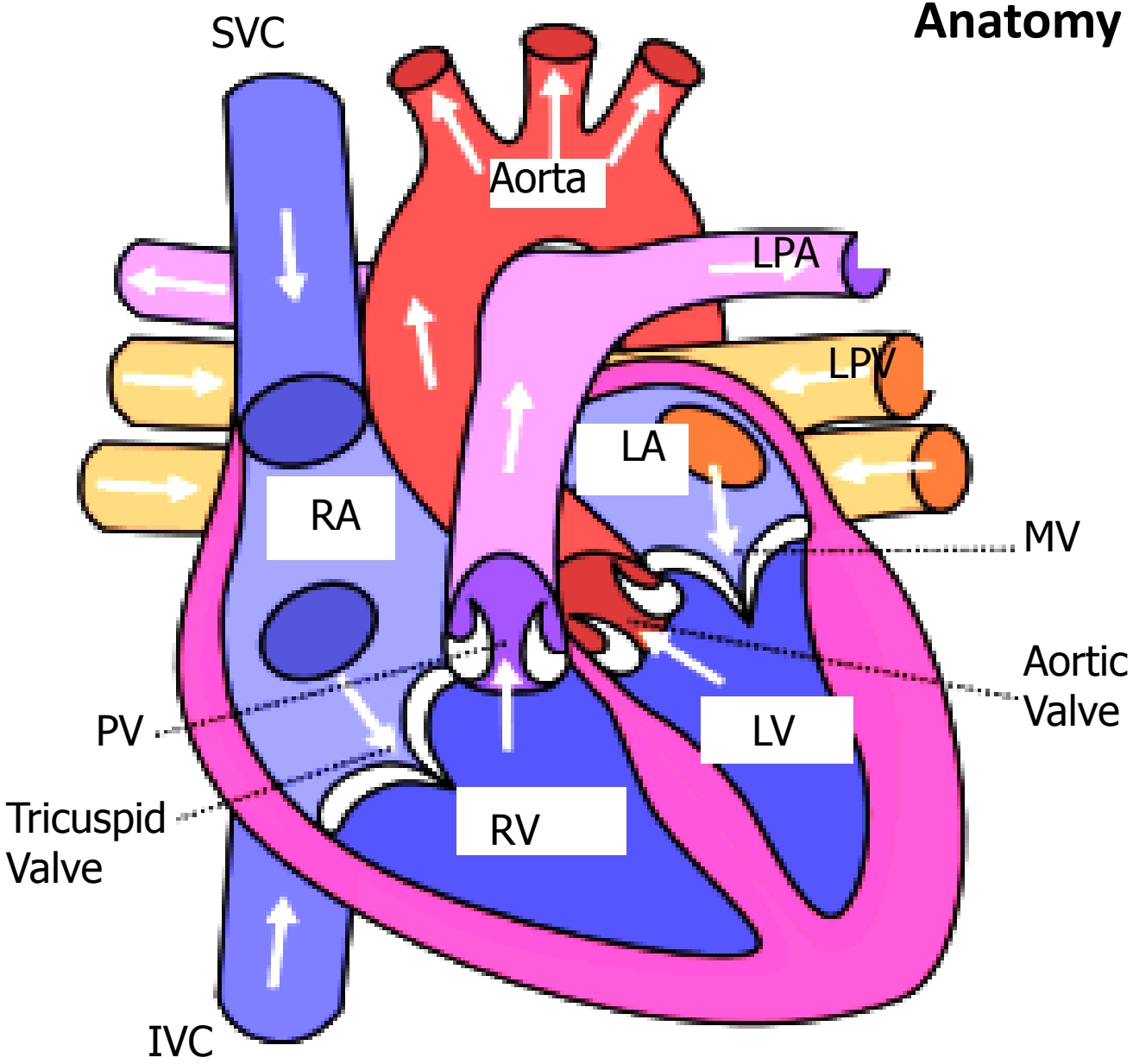
SVC
Aorta
LPA
LPV
LA
RA
MV
Aortic
Valve
PV
LV
Tricuspid
Valve
RV
IVC

Congenital Heart Defects

Acyanotic

volume load

left-to-right shunts

- atrial septal defect
- ventricular septal defect
- AV canal
- patent ductus arteriosus

pressure load

obstr. ventric. outflow

- pulmonary valve stenosis
- aortic valve stenosis
- coarctation of aorta

Cyanotic

↑ pulmonary flow

- transpos. of gr. vessels
- single ventricle
- truncus arteriosus
- total anomalous pulm. return w/o obstruction

↓ pulmonary flow

- tetralogy of Fallot
- pulmonary atresia
- tricuspid atresia
- total anomalous pulm. return w/ obstruction

modified from Bernstein (1996) and other sources

CHD: Pathophysiology

- Left to right shunts
  - Oxygenated blood recirculates in lungs
- Right to left shunts
  - Desaturated blood bypasses lungs
- Transposition
  - Circulations in parallel
- Obstruction
  - Increased workload on cardiac chamber

ASD

- Failure of complete closure of the interatrial septum

Atrial Septal Defects

1. Patent foramen ovale
2. Secundum ASD
3. Primum ASD
4. Sinus Venosus ASD
5. Coronary Sinus ASD
6. Common atrium

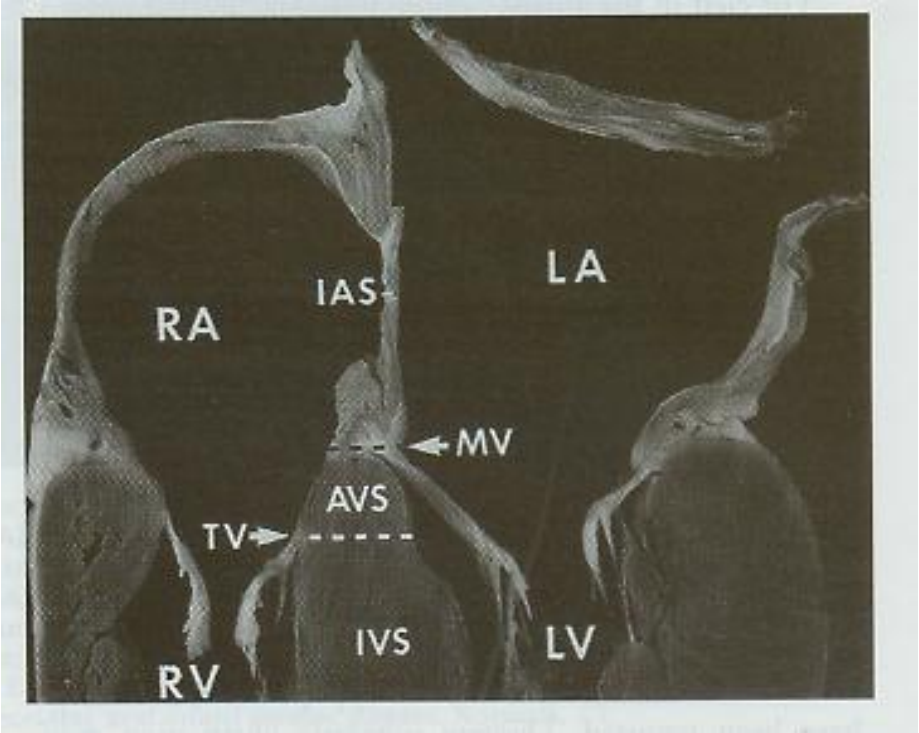

Atrial Septal Defect - physiology

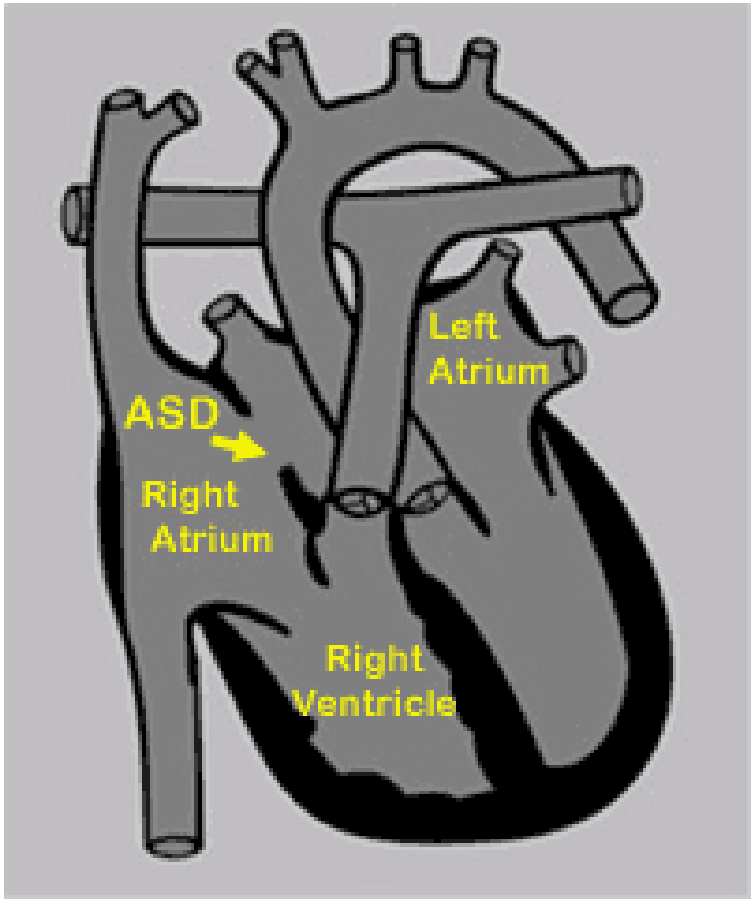

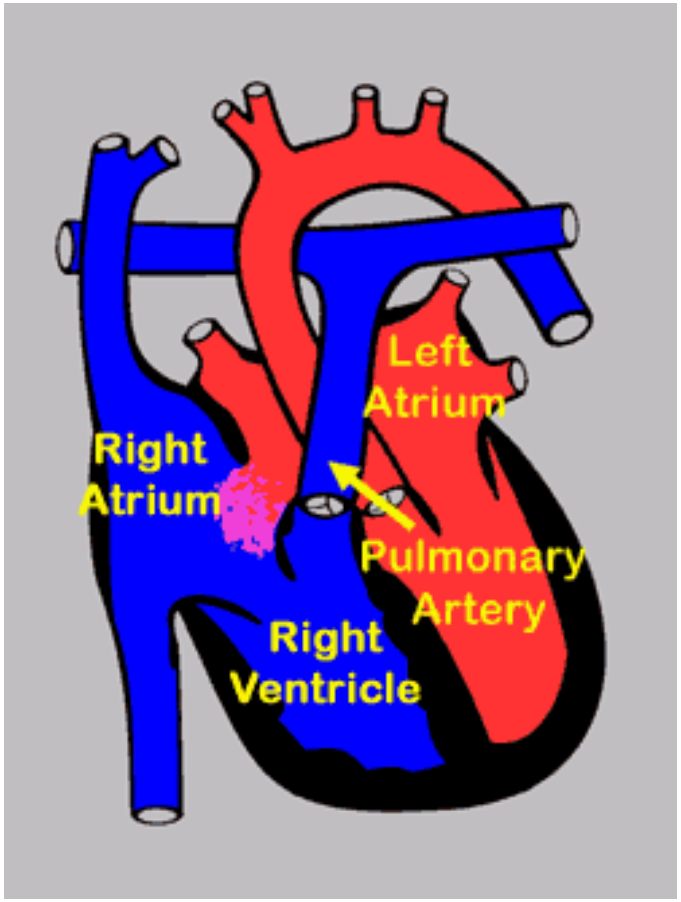

What causes the murmur?

ASD - Clinical Findings

- Usually asymptomatic
- Fixed widely split S2
- Systolic Ejection murmur at LUSB, radiates to lung fields
- Soft diastolic murmur at LLSB
- Precordial bulge and RV heave
- Prolonged P-R interval and IRBBB

Natural history and complications

- Spontaneous closure
  - Diameter<3-5mm
- Patent
  - Arrhythmia –atrial Fib
  - Heart failure
  - Pulmonary hypertension
  - Paradoxical emboli
  - Mitral valve prolapse

ASD treatment

- Surgical closure

- By device in the cath-lab



Ventricular Septal Defect

VSD Physiology

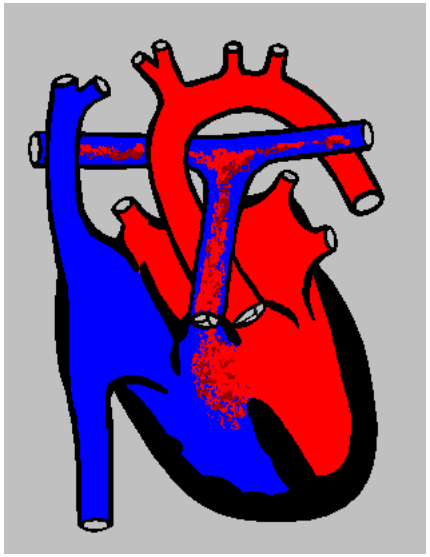

- Physiology is determined by size of VSD
- Small to medium size defects are pressure limiting or "restrictive"
- Large defects provide no resistance to flow between the ventricles - "non-restrictive"
- In large VSDs the flow across the defect is determined by the relative resistance in pulmonary and systemic vascular beds
- Patients with large VSD have pulmonary arterial hypertension
  - If low PVR, lots of flow, lots of symptoms
  - If high PVR, less flow, may be asymptomatic

Press = Flow x Resist

Clinical picture VSD

- Congestive heart failure
- Symptoms
  - Sweat during feeds
  - Difficulty in feeding
  - Inadequate weight gain

- 2-3 weeks
  - Tachypnea
  - Tachycardia
  - Mottled skin
  - Cold periphery
  - Enlarged liver

VSD COURSE

- Congestive heart failure
- Pulmonary hypertension
- Large VSD but balanced heart failure
- Spontaneous closure
- Develop RV outflow obstruction
- Aortic insufficiency
- Endocarditis

VSD - management

- Unrepaired VSDs do NOT need SBE prophylaxis
  - Practice good oral hygiene!
- Symptomatic defects - medical first
  - Diuretics, ACEI, nutrition, time
  - Perimembranous and muscular defects may have spontaneous closure
- Indications for interventions:
  - Failure of medical management
  - Aortic insufficiency
  - Qp/Qs > 2:1, volume load in older children
  - Pulmonary Hypertension - repair before 1 year of age
- Eisenmenger's - inoperable

VSD definitive management

- Catheterization
  - device closure
- Surgery
  - closure

Ventricular Septal Defect

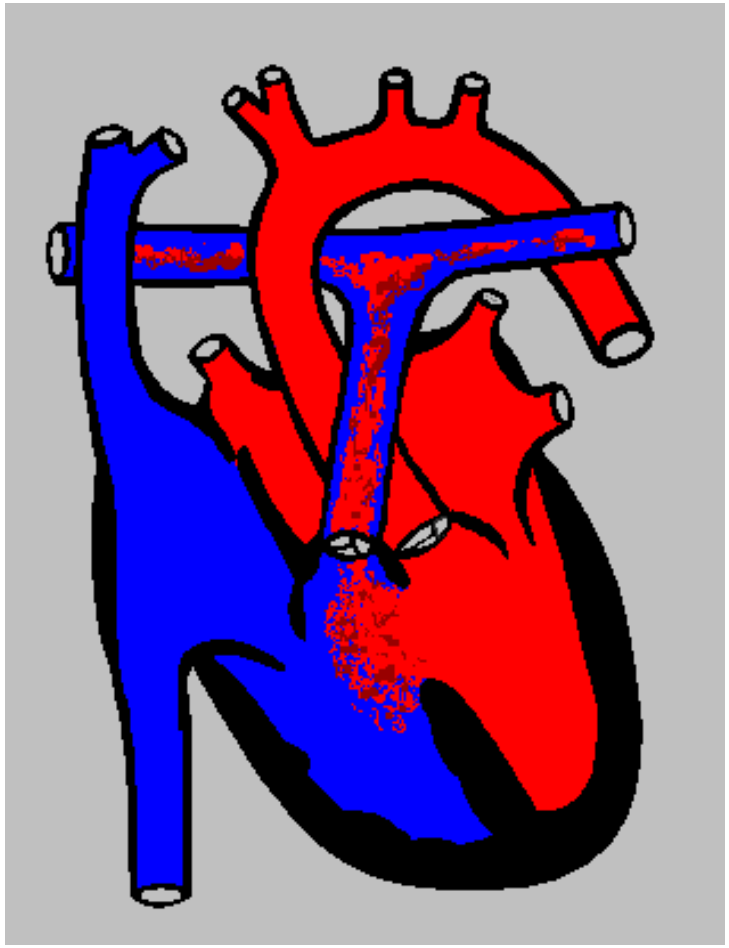

VSD before surgical repair

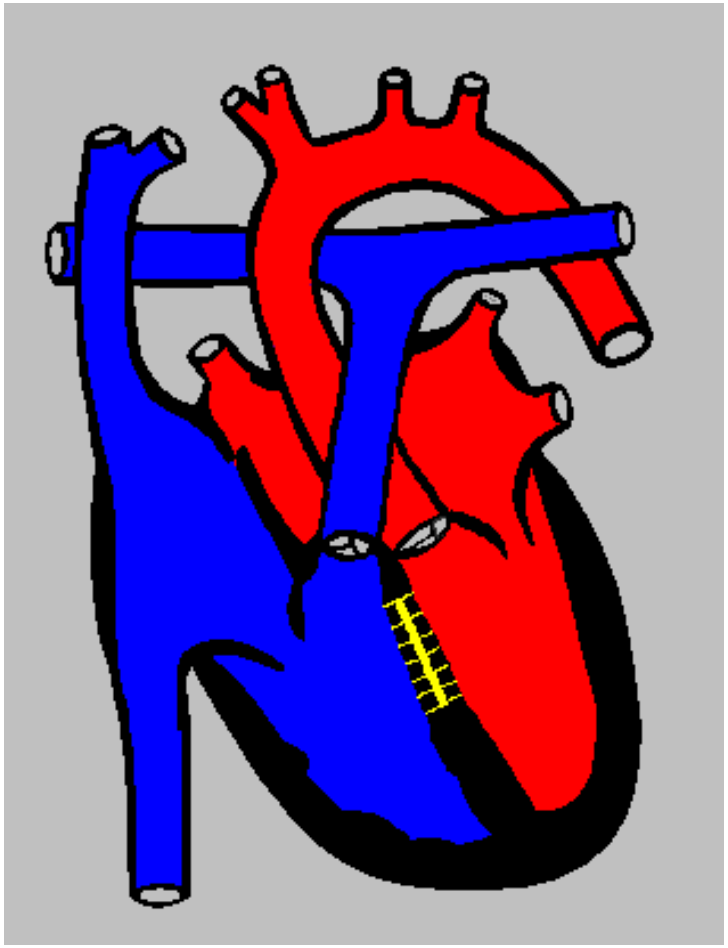

VSD after surgical repair

COARCTATION OF THE AORTA

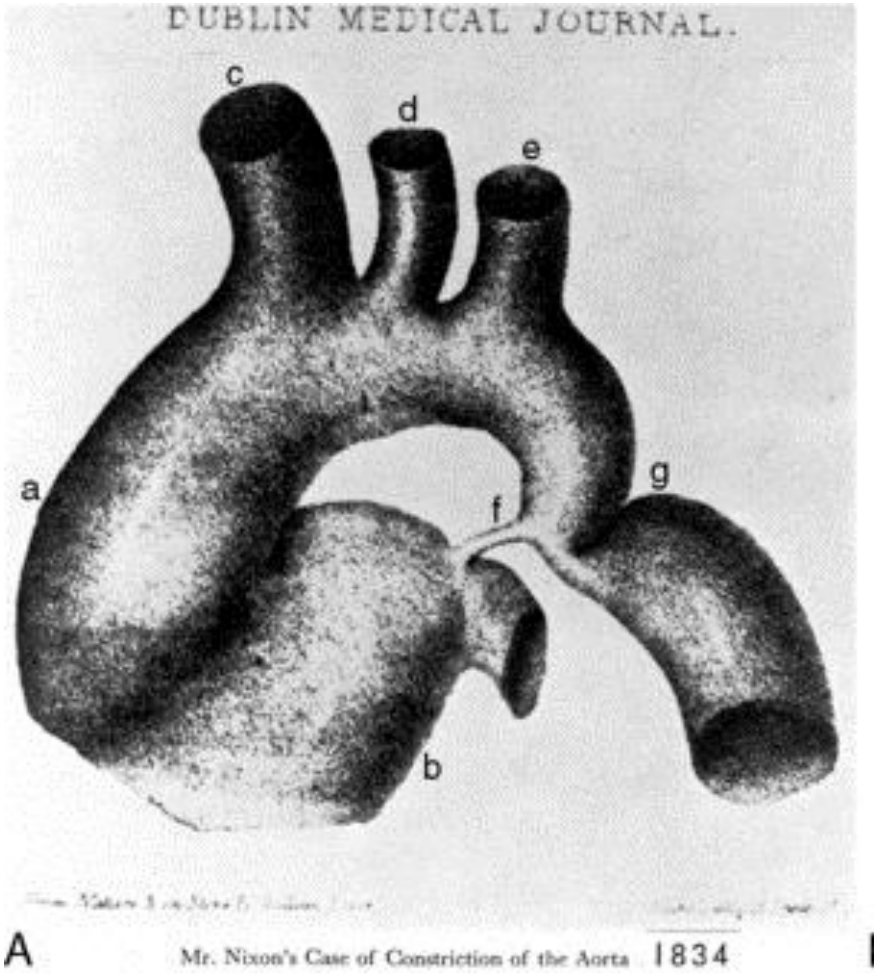

- Congenital narrowing of the aorta
  - Most typically at the isthmus
- Discrete shelf or longer segment narrowing

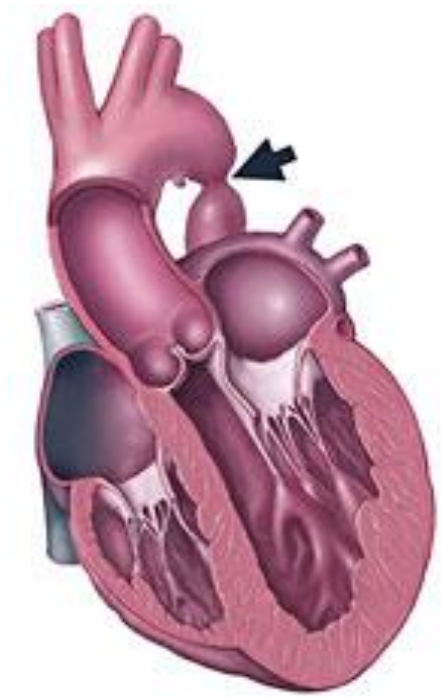

Coarctation – associated lesions

- 85% have associated Bicuspid Ao Valve
- “Simple coarctation”
  - In older patients, usually
  - In infants, half are “simple”
- “Complex coarctation” – associated with other intra-cardiac lesions
  - VSD
  - Valvular/sub-valvular Ao Stenosis
  - Shone’s complex
  - TGA with VSD
  - ASD
  - Single ventricle

Coarctation Variations

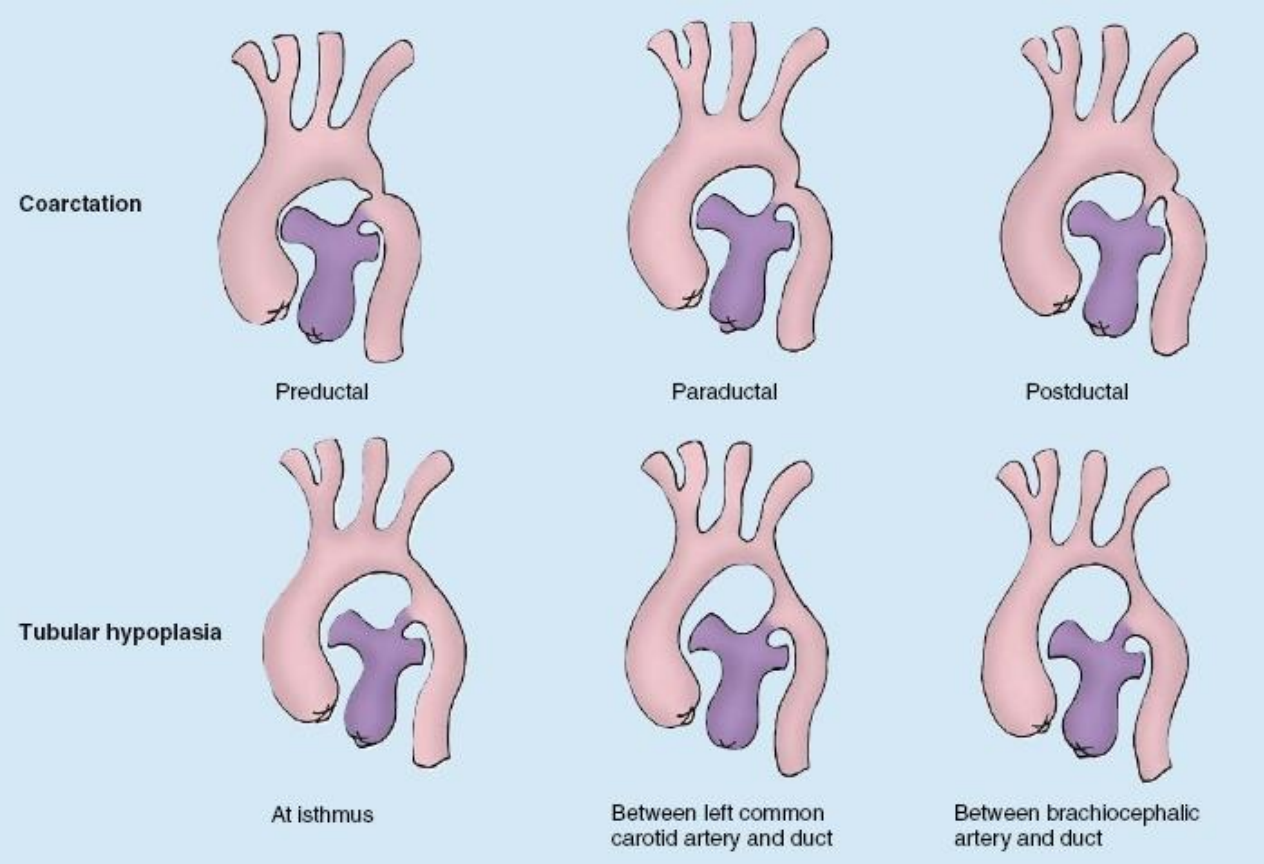

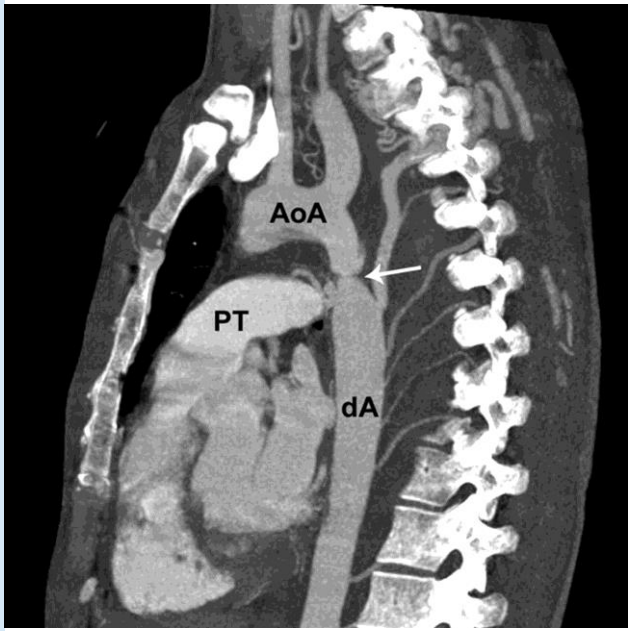

Hemodynamics

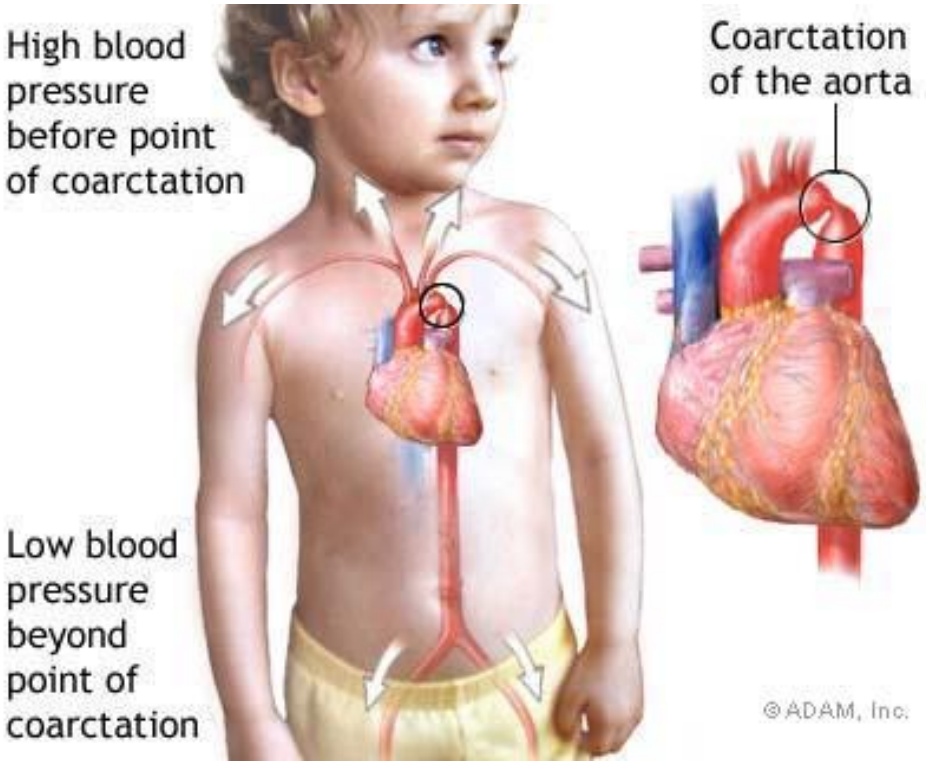

- Low flow to kidneys activates renin-angiotensin system resulting in high BP above the obstruction and normalized BP below

Collaterals often develop

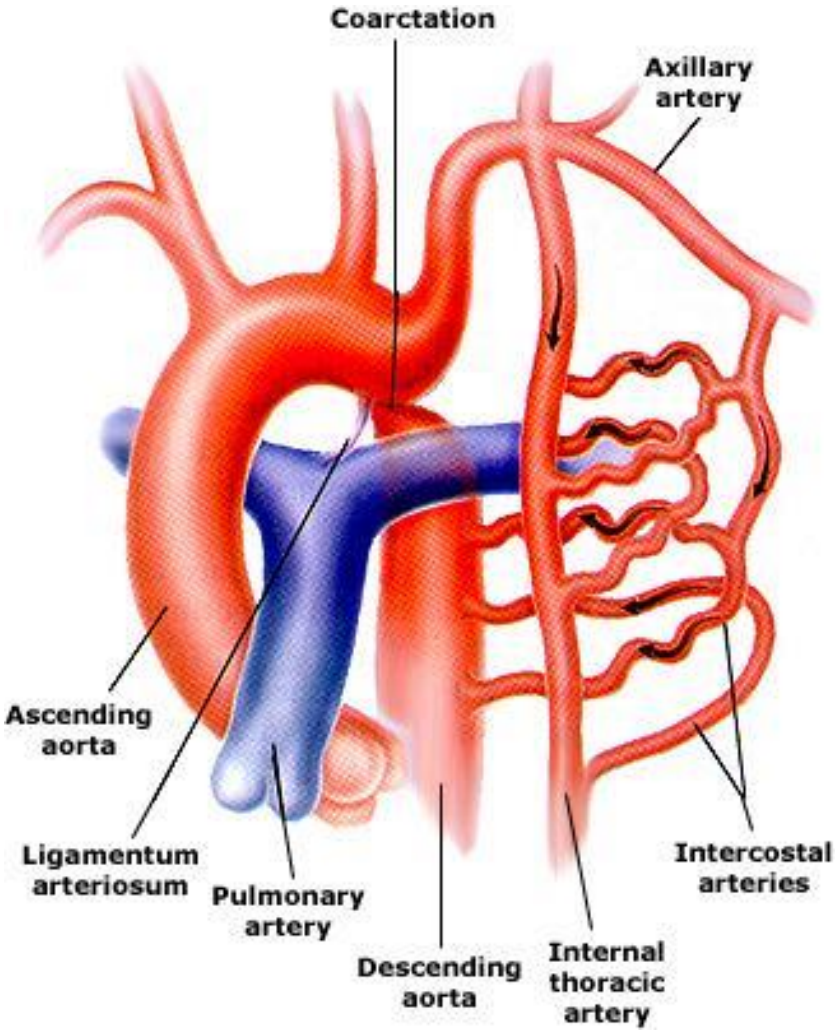

Newborn presentation

- **Dyspnea, poor feeding, diaphoresis, pallor, tachycardia, poor pulses, murmur, usually within first 2 weeks of life**

- Upon ductal closure,
  - Obstruction in descending aorta develops rapidly with no time to develop hypertrophy
- Systolic dysfunction, poor CO
- Increased EDP
  - increased LA pressure,
  - pulmonary venous congestion
- Congestive heart failure with acidosis, shock
- Associated lesions compound the burden (aortic stenosis, VSD, etc)
- Rx: Prostaglandin E1, stabilize, surgery

Coarctation late presentation

- Late presentation (older child or adult)
  - Referred for murmur, high BP or Turner's
  - Asymptomatic (rarely headache or claudication)
  - Decreased, delayed pulses in lower extremities
  - 3-4% have anomalous R subclavian artery (ARSA)
    - Arises distal to coarctation so remember to check pulses in all 4 extremities
    - Compare right and left
  - Systolic BP difference in upper and lower extreme
    - measure supine with correct cuff size
  - Gradient may be mild (<20 mmHg) or severe (as high as 80 mmHg)

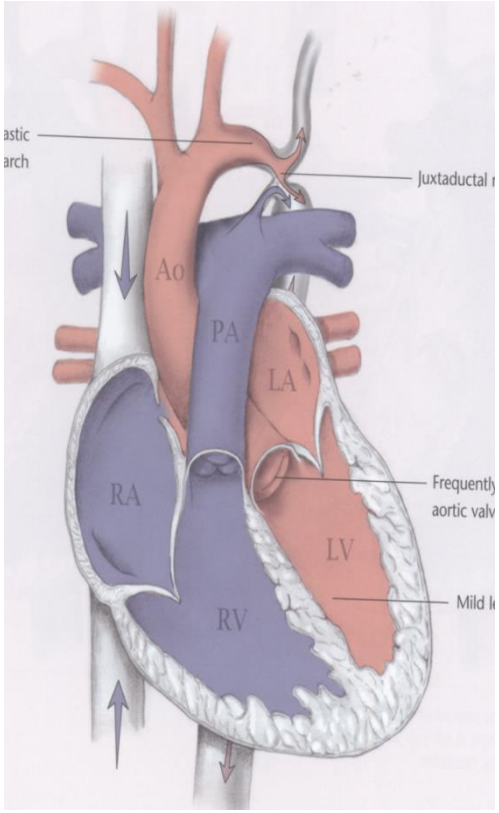

Presentation in older child/adult - continued

- Prominent impulse at apex
- Thrill
- Normal S1 and S2, ejection click (if BAV)
- 2-3/6 SEM at LUSB radiates to Left scapula
- Continuous murmurs throughout chest from collaterals
- Systolic BP difference in upper and lower extremities (measure supine with correct cuff size)

Treatment

- **Surgery** – various techniques
  - For all newborns
  - Some older patients
  - Requires cross clamping aorta with risk of spinal ischemia
  - Risk increases if poorly developed collateral circulation
- **Primary balloon angioplasty**
  - Procedure of choice for re-stenosis after surgery
  - For selected children with discrete shelf - controversial
  - Risk of dissection, late aneurysm formation
  - Considered palliative only in small neonates
- **Percutaneous stent**
  - For fully grown patients
  - Reduces risk of aneurysm
  - Suitable for long segment stenosis

Endovascular stent for coarctation

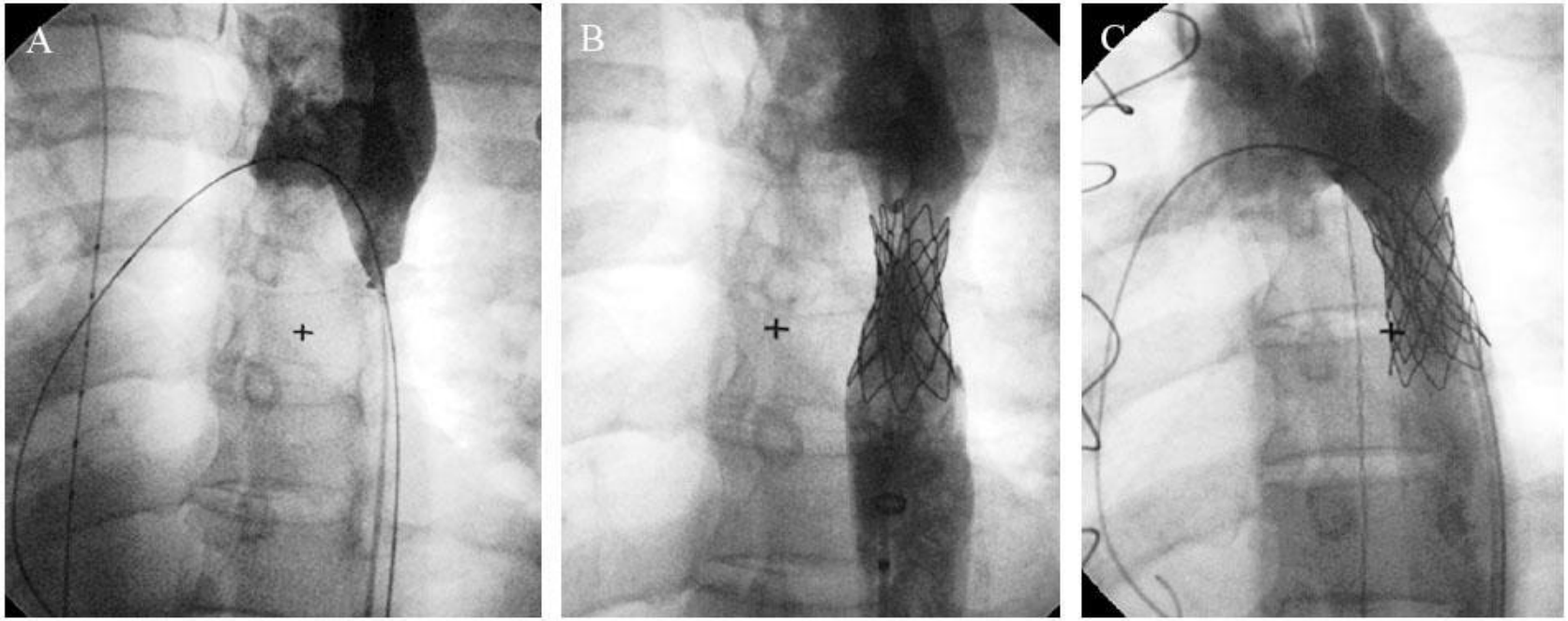

Figure 1. *Descending aorta angiogram in the frontal projection in a 26-year-old female patient (weight = 77 kg) with severe coarctation of the aorta, with a peak gradient of 35 mmHg.* **(A)** *Angiogram using a Multitrack catheter demonstrating tight coarctation (arrow) with a diameter < 1.5 mm.* **(B)** *Repeat angiogram after deployment of a 34 mm Cheatham Platinum stent mounted over a BIB catheter (inner balloon diameter 6 mm and outer balloon diameter of 12 mm), demonstrating a good result (arrow).* **(C)** *Final angiogram after further expansion with a 18 mm ZMED balloon demonstrating further expansion of the stent to a diameter of 14 mm and a gradient reduction to zero.*

Serially expanded up to 14 mm diameter with reduction in gradient to zero

Patent Ductus Arteriosus
(Friend or Foe?)

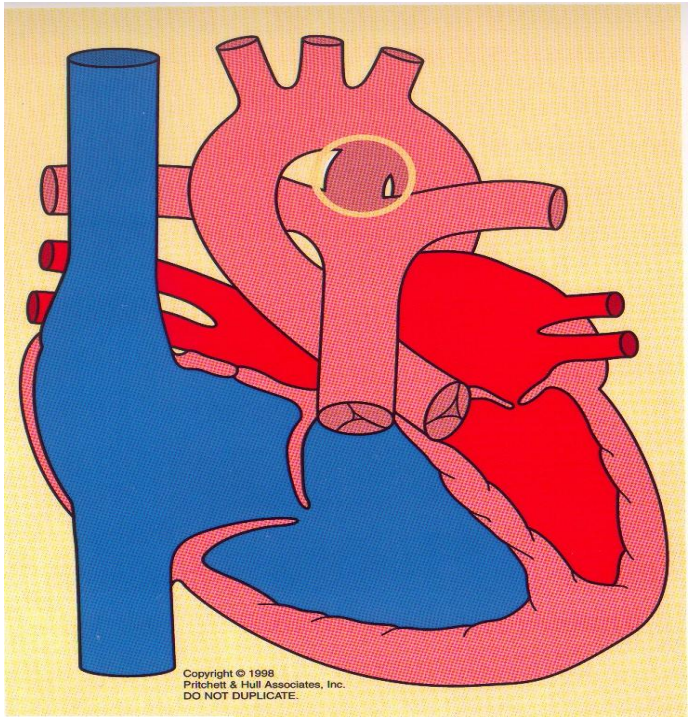

Magnitude of shunt depends on

1. Pressure gradient
    - Ao and PA

2. Resistance within PDA

Before Birth

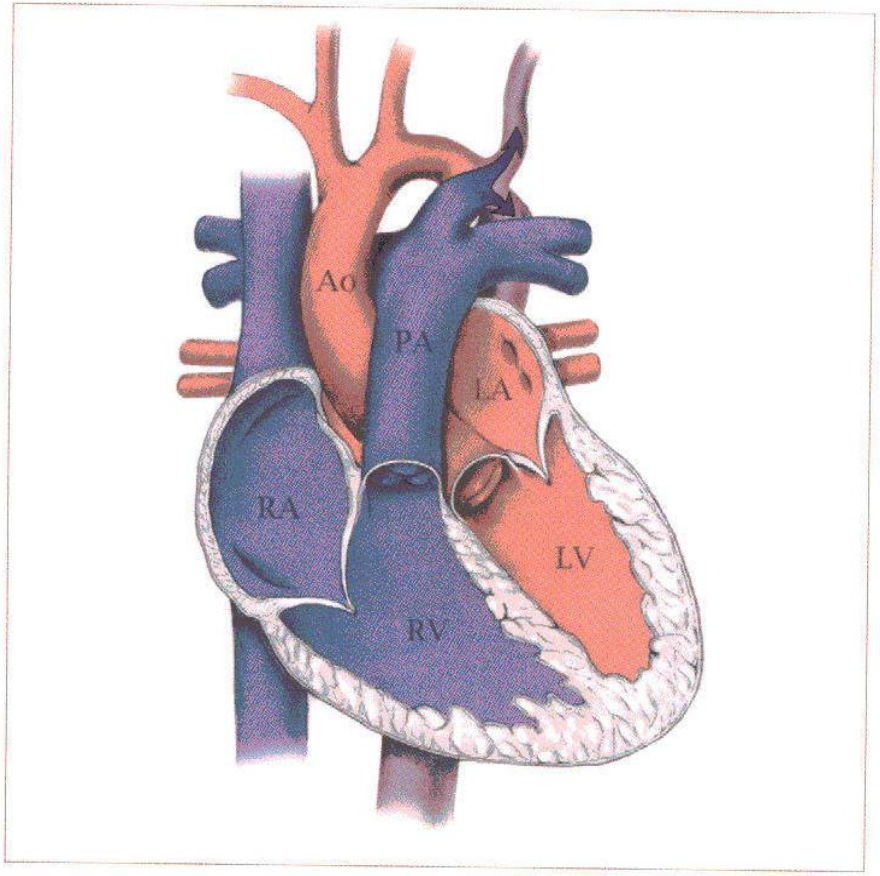

Figure 2.23. Illustration demonstrating a right-to-left shunt at the ductus arteriosus. Deoxygenated blood flows into the pulmonary artery, where variable amounts of blood shunt through the ductus arteriosus to the aorta.

After Birth

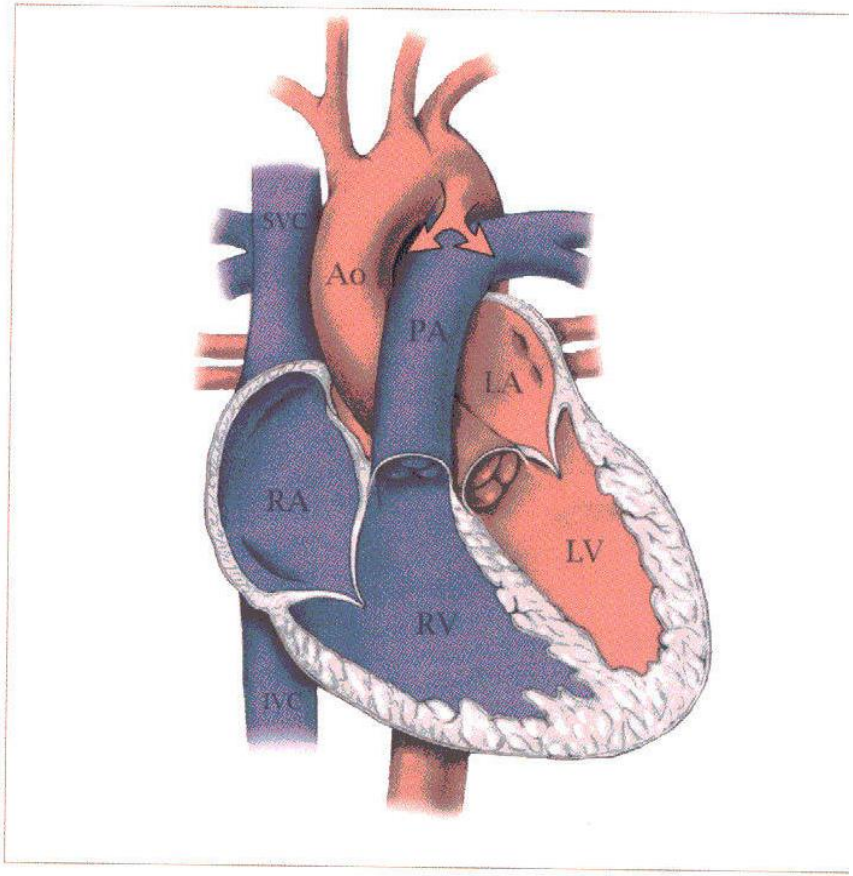

Figure 2.24. Illustration demonstrating a left-to-right shunt at the ductus arteriosus. Oxygenated blood flows through the aorta, with variable amounts of blood shunting through the ductus arteriosus into the pulmonary arteries and lungs.

PDA pathophysiology

- Pulmonary over-circulation
- Decreased lung compliance (increased WOB)
- Increased pulmonary venous return to LA
- Left heart enlargement
- Diastolic run-off in aorta with low diastolic BP
- Eventual pulmonary vascular disease (Eisenmenger's)
- May present with murmur, CHF, A. fib, endocarditis, or as an incidental finding
- Rarely there is an aneurysm of the ductus which may rupture or impinge on recurrent laryngeal nerve

PDA and Recurrent Laryngeal Nerve

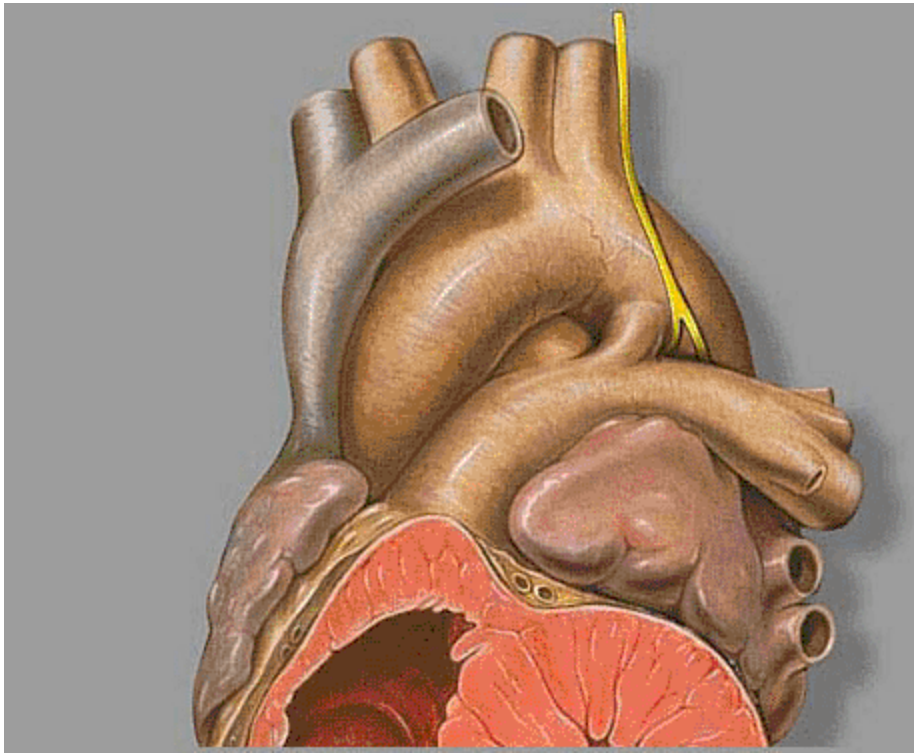

Large PDA

- PVR < SVR
  - But pressures may be equal if ductus is large enough
    - "Non restrictive"
- Signs of CHF
  - FTT, poor feeding, resp distress, fatigue in older child
- Palpation
  - Dynamic LV impulse and thrill
- Bounding pulses with wide pulse pressure
- loud continuous murmur "Machinery" at LUSB or L infraclavicular area
- (Apical diastolic rumble)

PDA Treatment

- Medical management of Heart failure
  - diuretics, afterload reduction, nutrition
- Surgical Ligation (standard or thoracoscopic)
  - symptomatic infants
  - older patients who are not candidates for transcatheter based therapy
- Catheterization
  - Coil occlusion,
  - Amplatzer device
  - Other devices

- Pulm vasodilators for pts with Eisenmenger's

When the ductus is your friend

Ductal Dependent Lesions

(In CHD)

- Right heart obstruction
  - Need PDA for pulmonary blood flow
    - Critical PS, TOF, PA, TA
- Left heart obstruction
  - Need PDA for systemic blood flow
    - Critical AS, CoArc, HLHS, IAA
- PDA needed for mixing
  - dTGA

Atrioventricular Canal Development

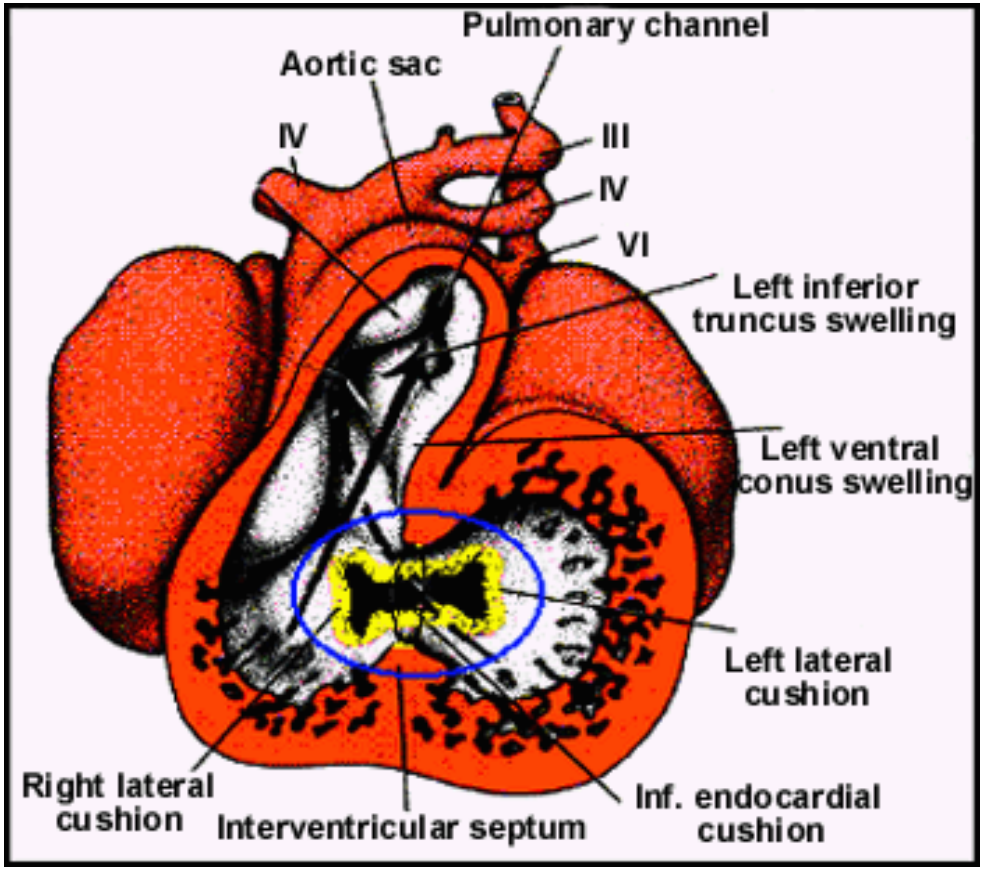

Complete AV Canal

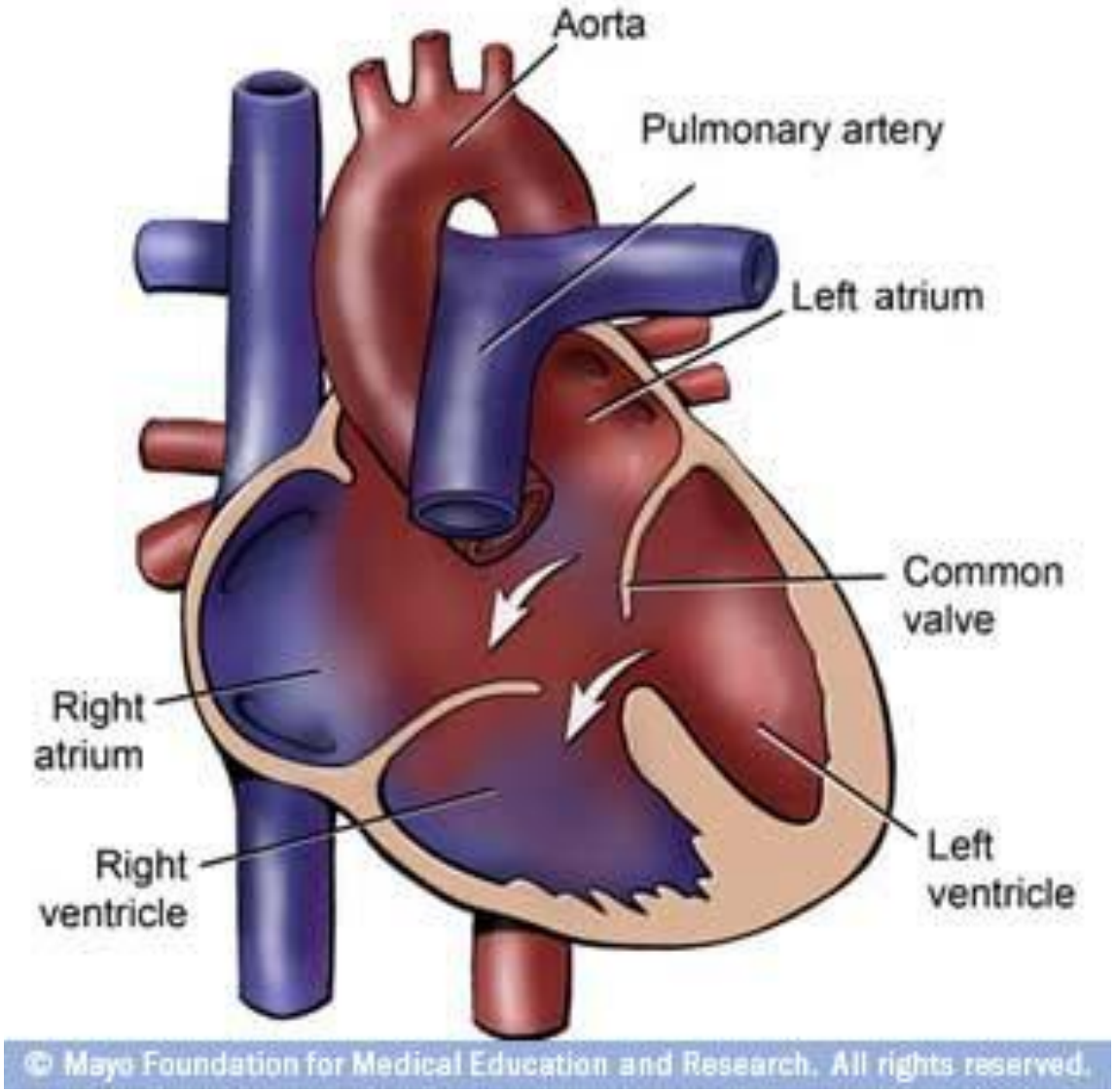

Associated with:
1. Trisomy 21

Valve Stenosis

Anatomy

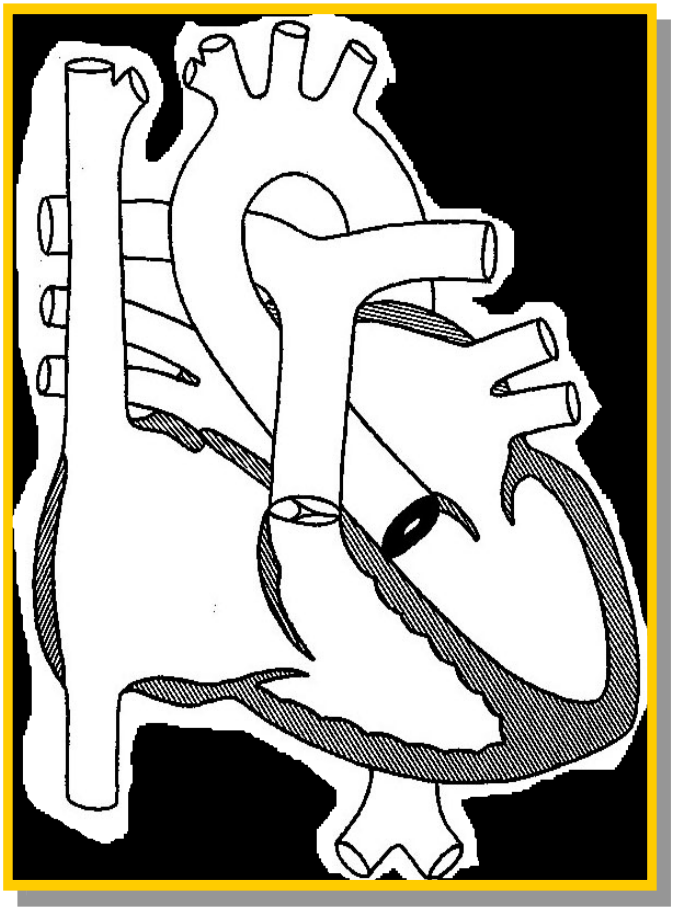

Obstructive physiology

- Numerous levels of obstruction
  - » Valve (90%)
  - » Subvalve
  - » Supravalve

Valve Stenosis

Clinical manifestations

General

- Variable presentation

  Asymptomatic → CHF/Cyanotic

- Murmur
  - Systolic, crescendo-decrescendo
  - Localized to valve
  - Radiates with flow of blood
  - Click

(.wav)

Cyanotic Heart diseases

Reasons for central cyanosis

- Right to left shunting in the heart
- Right to left shunting in the lungs
- Methemoglobinemia

Hyperoxic test

- Empiric
- Administration of 100% O_2 for 10 minutes
- Blood gas PO_2

State	Saturation	PaO_2 after 10 mins of 100% O_2
Normal	90-100	400-500
Cy. HD	<80	<150
Mixed	<100	<250
Respiratory	>80	>150

Intracardiac Rt. To Lt. shunting

- Parallel circulations
  - Transposition of the great vessels
- Reduced pulmonary blood flow
  - Tetralogy of Fallot
  - Pulmonary Atresia
- Complete mixing normal or increased pulmonary blood flow
  - Single ventricle

Tetralogy of Fallot

- **1.VSD**
  - large, unrestrictive
  - malalignment type
- **2. Overriding Aorta**
- **3. Pulmonary Stenosis**
  - infundibular
  - valvular
  - hypoplasia of PAs
- **4. RVH**

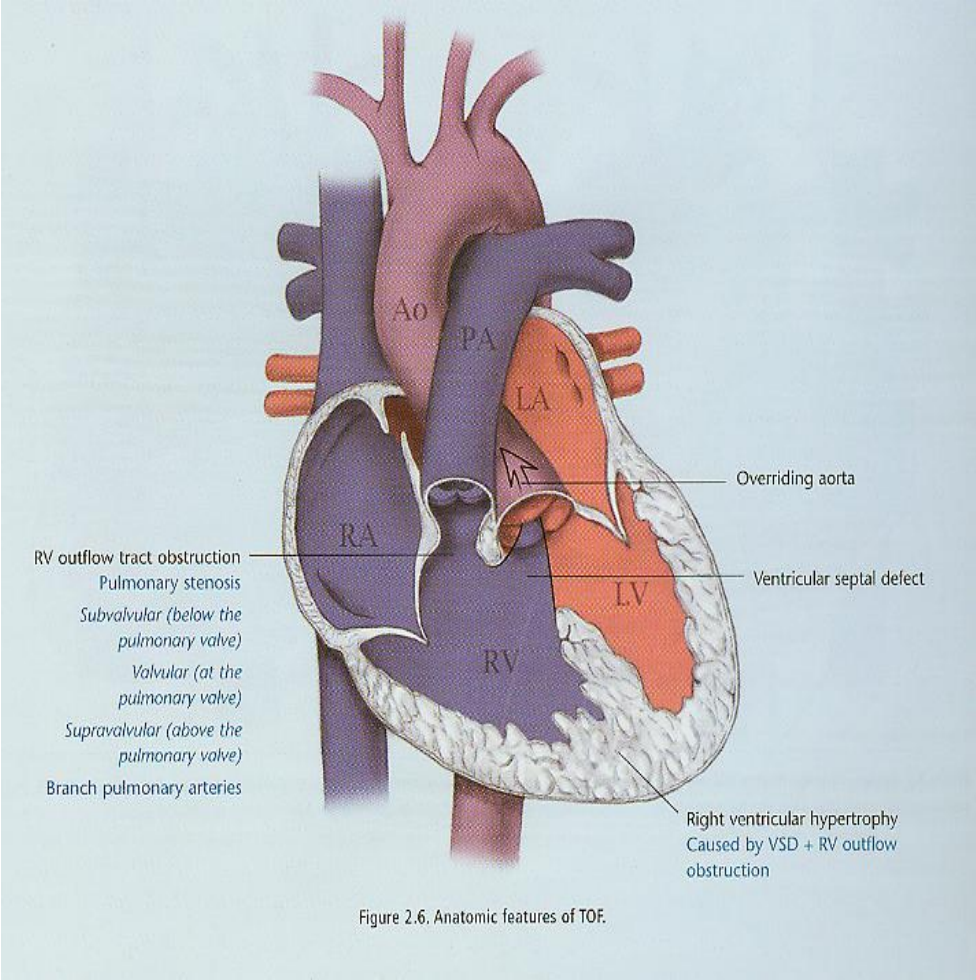

Figure 2.6. Anatomic features of TOF.

Anterior deviation of the infundibular septum

Physiology

- VSD is non-restrictive
- direction and magnitude of shunt depends on severity of RVOT obstruction
  - Severe RVOTO: more R to L shunt
  - Mild RVOT: less R to L shunt
- RVOT obstruction may be dynamic
- “Pink Tet” if RVOT obstruction is minimal, net L to R shunt, behave like a large VSD

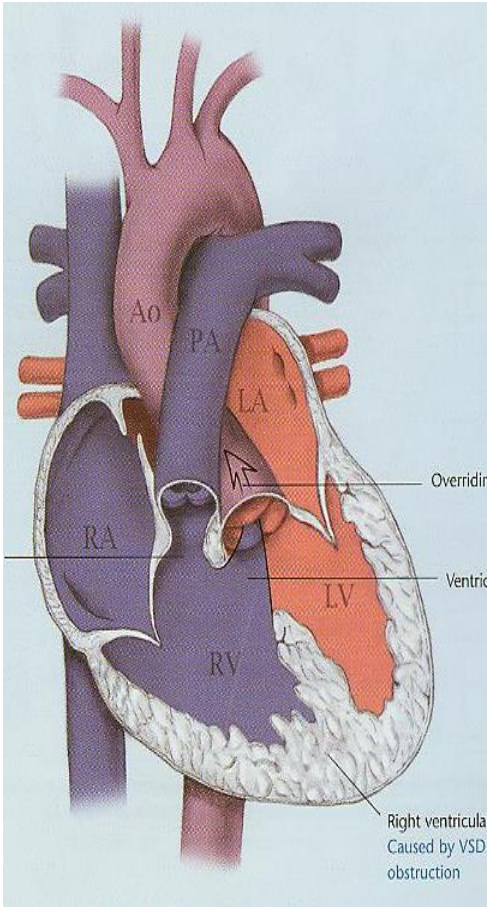

Clinical Presentation

- Newborn presents with murmur or cyanosis
- O_2 Sat gradually declines over time
- Hypercyanotic Spells
  - acute onset of intense cyanosis with hyperpnea due to spasm of the infundibulum
  - Decreased PBF, severe hypoxemia, altered level of consciousness, very high mortality
  - Rx: Calm, O_2, knee chest, phenylepherine, surgery, b-blocker
- ECG - RVH, RAD (RBBB after repair)
- S&S: Squatting, clubbing (unrepaired), cyanosis

CXR in TOF

- heart size small or normal
- upturned apex
- concave LUSB
- “boot shaped”
- Right Aortic Arch – 25%
- normal or decreased vascular markings

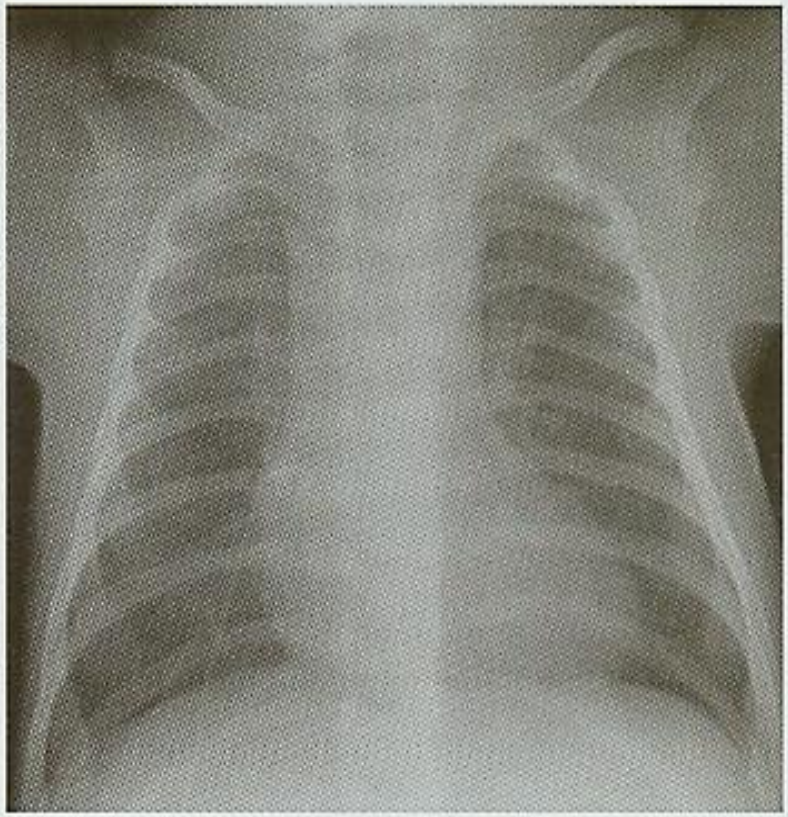

Figure 2.9 Chest x-ray of a newborn with TOF. The pulmonary vascular markings are not decreased, reflecting adequate pulmonary blood flow. A normal-sized “boot-shaped” heart is apparent.

Tetralogy of Fallot

"Tet Spells"

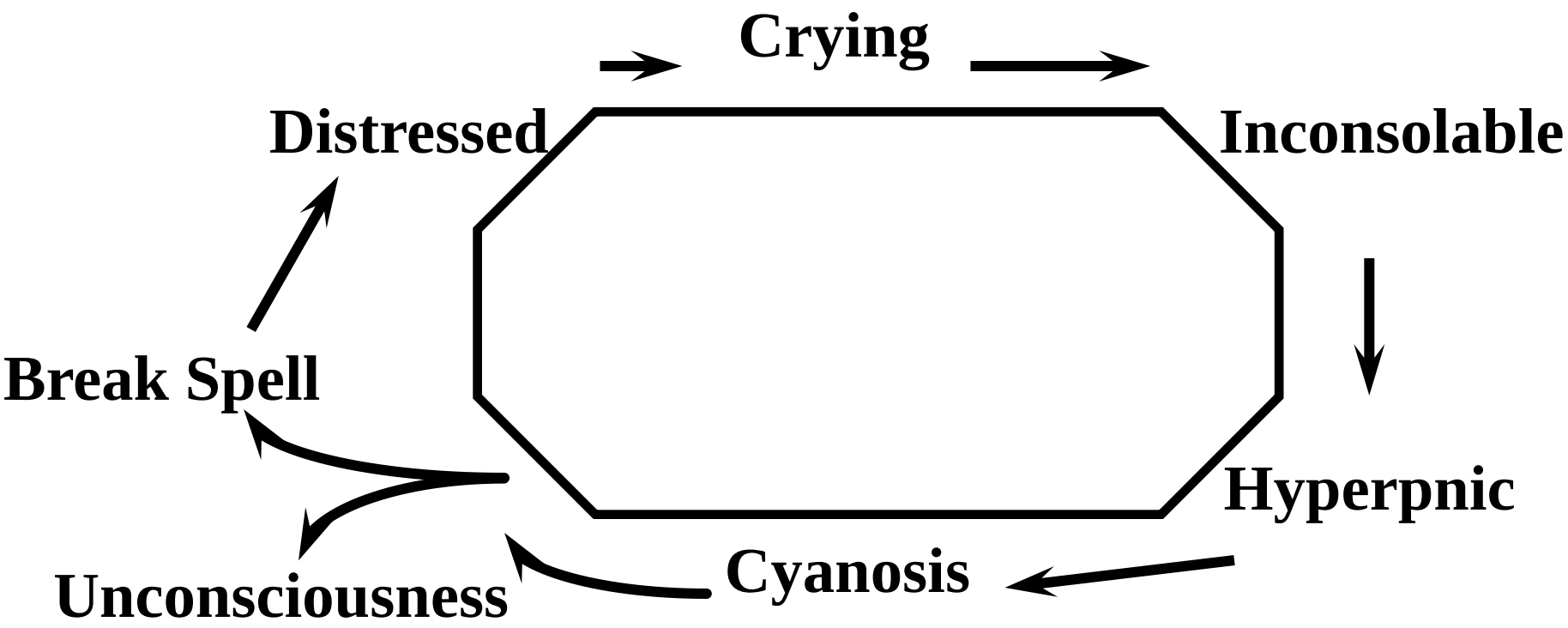

Tetralogy of Fallot

"Tet Spells"

Treatment

- Avoid agitation
- Knee chest
- Volume
- Sedation (morphine/ketamine)
- Propranolol
- Phenelyepherine
- Emergency surgery

TGA

Transposition of the Great Vessels

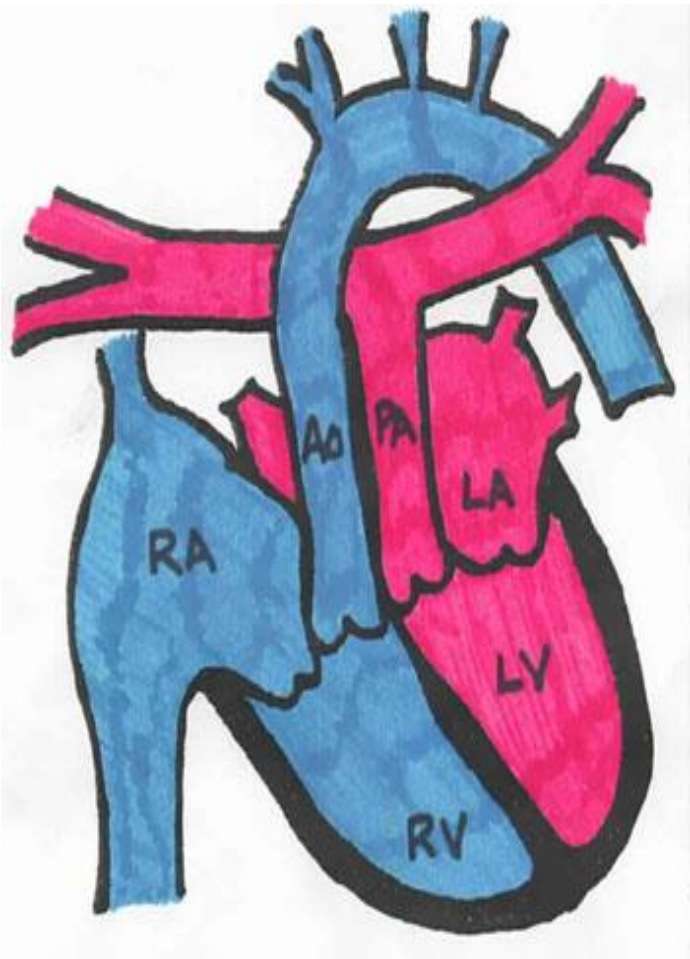

- Normal “dextro” looping of ventricles abnormal rotation of the great arteries
- Atrio-ventricular concordance with ventriculo-arterial discordance
  - Pulmonary arises from left ventricle
  - Aorta arises from right ventricle
- Simple dTGA
- Complex dTGA – associated lesions
  - VSD
  - ASD
  - PDA
  - Valve stenosis
  - Coronary anomalies frequent

TGA Presents at birth with severe cyanosis

Mixing occurs at ASD/PFO, PDA and VSD, if present

Immediate stabilization:

1. Start PGE1 (since the 1980's)
2. Balloon Atrial Septostomy

Truncus Arteriosus

Truncus Arteriosus

Anatomy

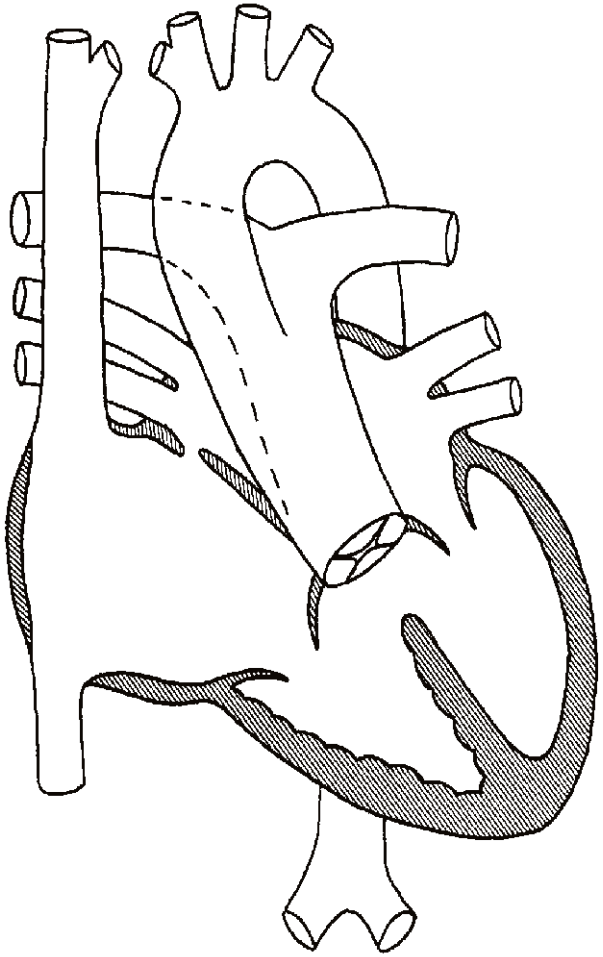

Left to right shunt

- Single arterial trunk supplies pulmonary and systemic circulation
- Ventricular septal defect

Univentricular Hearts
“single ventricles”

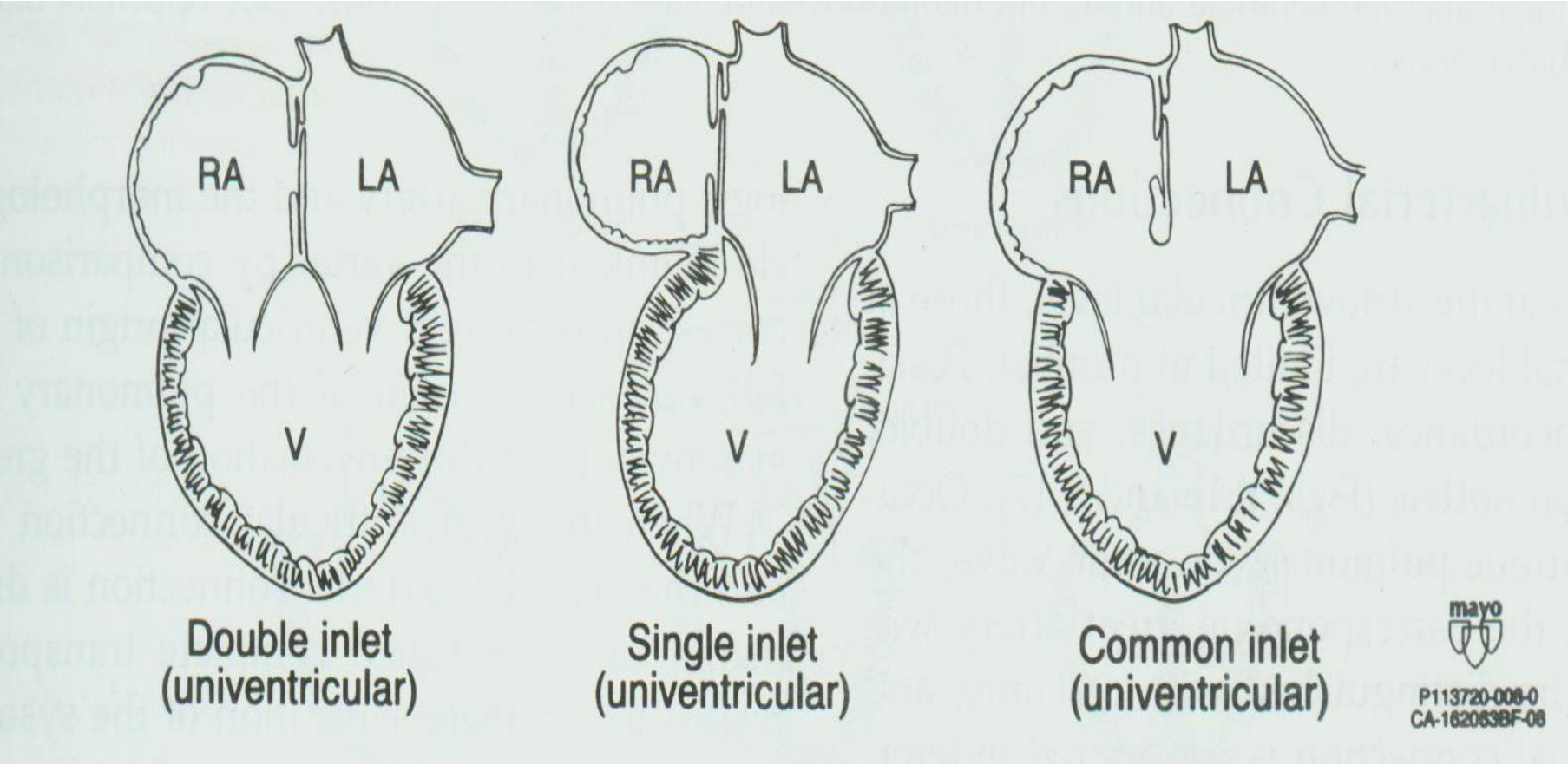

Tricuspid Atresia

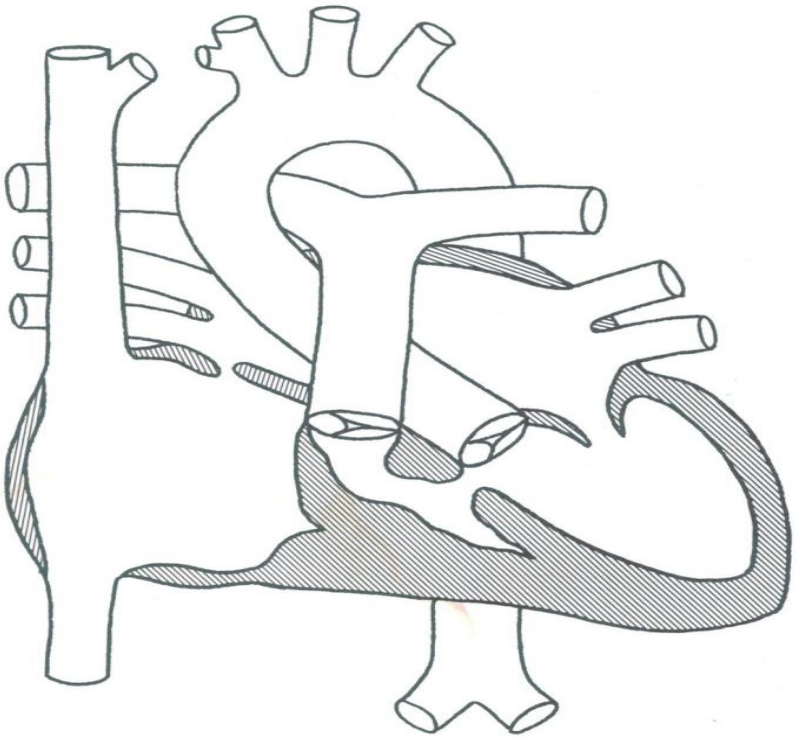

Hypoplastic left heart

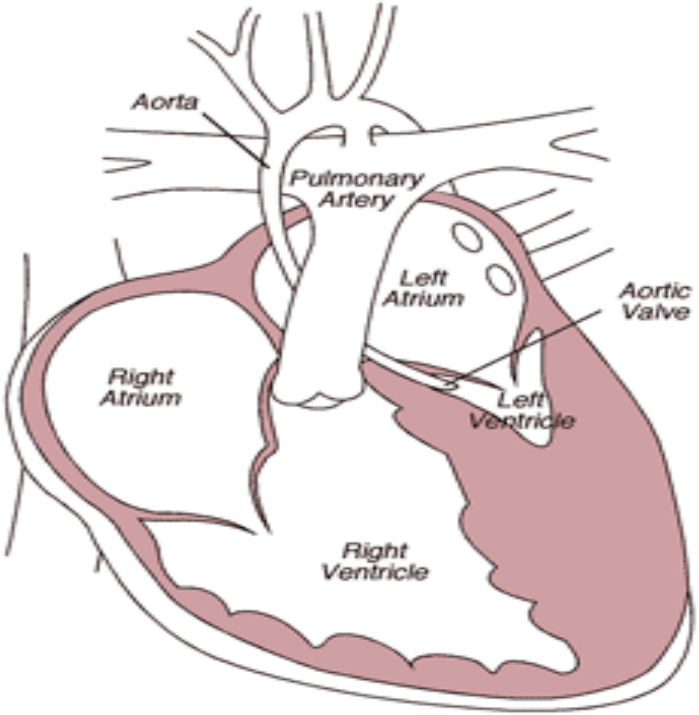

Total Anomalous pulmonary venous Connections (TAPVC) or Return (TAPVR)

Pulmonary Venous Anomalies

- Total Anomalous pulmonary venous Connections (TAPVC)
  - Failure of normal connection between pulmonary venous plexus AND CPV before splanchnic venous system have regressed.
  - Type I: Supracardiac (47%)
  - Type II: Cardiac (16%)
  - Type III: Infradiaphragmatic (13-23%)
  - Type IV: Mixed((7-10%)

Supra Cardiac TAPVC

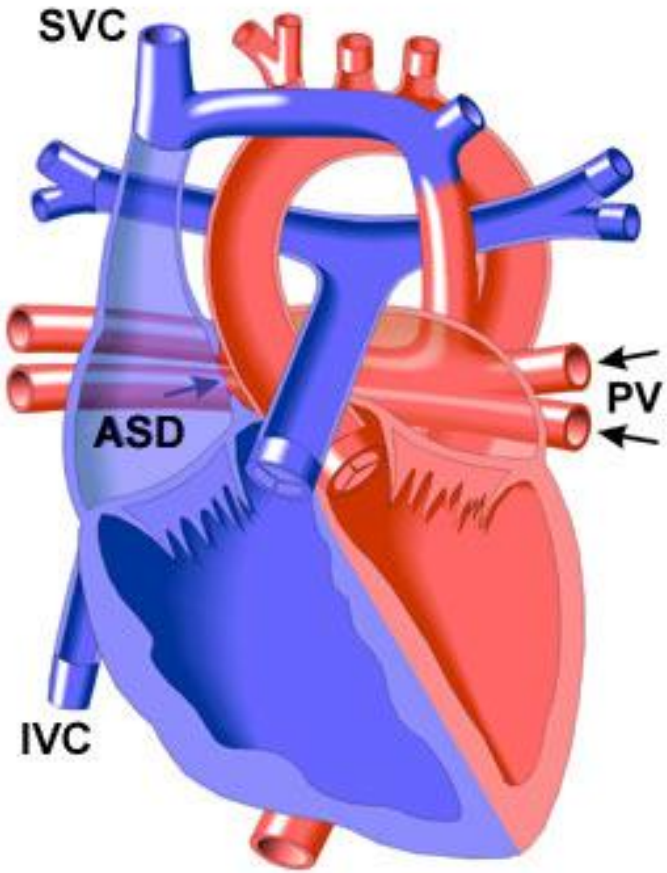

Infra Cardiac TAPVC

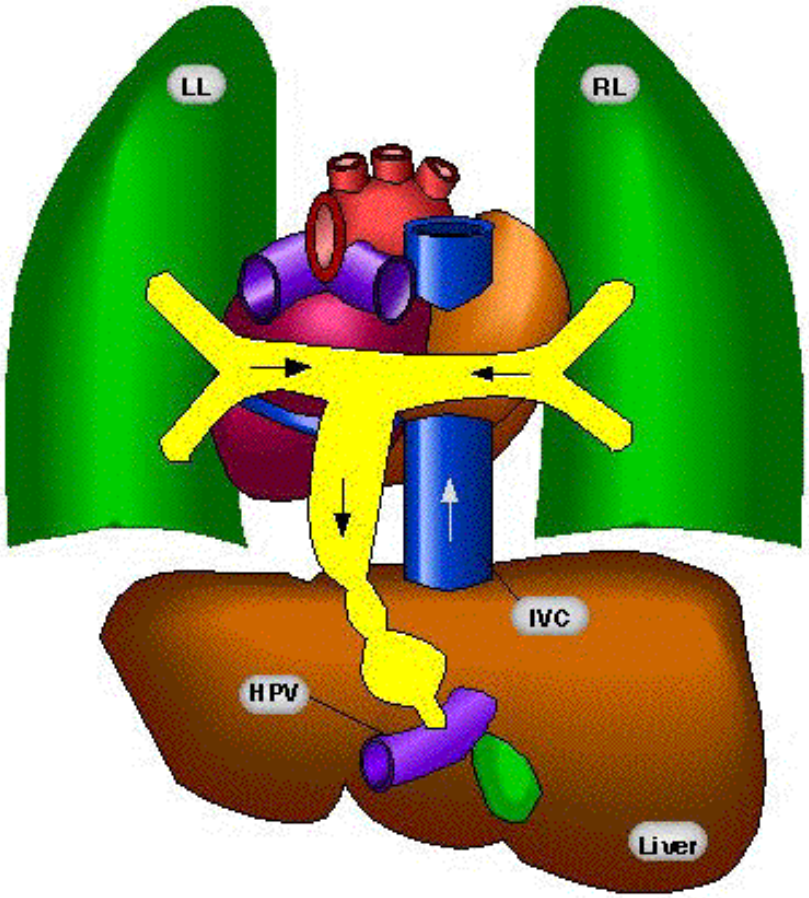

Pulmonary Venous Anomalies

- Pathophysiology
  - Dependent on Anatomy, mixing and obstruction
  - Obstruction:
    - Pulmonary edema,
    - Reflex vasoconstriction,
    - Vascular remodeling,
    - RV changes and failure

Thank you